

Date Printed: 06/21/2012

Time Printed: 07:52:26

MIDAMERICA ORTHOPAEDICS

75 REMITTANCE DR STE 6015

CHICAGO IL 60675

Tax Id#: 263727319

Group#: MAO

Page 1

Inv#	Servdate	Ap	Dept	Dr	Fac	Ref	Proc	M1	M2	Desc	Diag 1	Ins/Comment	Amount	Resp Bal	Ins Bal
Patient#: 1002454 DULBERG, PAUL R.															
1	12/02/11	1		MGT	LIMP		99203			OFFICE OUTPT	906.1	AMOI X 2	230.00	.00	230.00
2	01/06/12	1		MGT	LIMP 735		99213			OFFICE OUTPT	906.1	AMOI X 1	160.00	.00	160.00

1) Group# MAO MIDAMERICA ORTHOPAEDICS

--> Resp Charges : .00

--> Ins Charges : 390.00

--> Charges : 390.00

Pays : .00

Pays : .00

Pays : .00

Adjs : .00

Adjs : .00

Adjs : .00

Bal Due : .00

Bal Due : 390.00

Bal Due : 390.00

Grand Totals :

--> Resp Charges : .00

--> Ins Charges : 390.00

--> Charges : 390.00

Pays : .00

Pays : .00

Pays : .00

Adjs : .00

Adjs : .00

Adjs : .00

Bal Due : .00

Bal Due : 390.00

Bal Due : 390.00

Parameters Used To Select This Report :

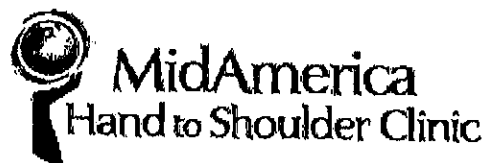REPORT OPTION : Detail

FREELINE OPTION : No Freelines

ADDITIONAL DATA OPTION : No Additional Information

First Selection Parameters:

CPT copyright 2009 American Medical Association. All rights reserved.



OAKBROOK TERRACE
1 TransAm Plaza Drive,
Ste. 460
Oakbrook Terrace, IL 60181
P 830.317.7007
F 630.317.7088

LOCKPORT
18810 W. 159th St.
Ste. 103
Lockport, IL 60441
P 708.237.7200
F 708.237.7201

PALOS HEIGHTS
10330 S. Roberts Road
Palos Hills, IL 60465
P 708.237.7200
F 708.237.7201

LIBERTYVILLE
1419 Peterson Road
Libertyville, IL 60048
P 847.247.0547
F 847.247.0540

SCHAUMBURG
1990 East Algonquin Rd.
Ste. 200
Schaumburg, IL 60173
P 847.303.5790
F 847.303.5795

HISTORY & PHYSICAL

PATIENT: Dulberg, Paul **AGE:** 41 years old **EXAM DATE:** 12/02/11

CHIEF COMPLAINT: Right forearm pain.

HPI: Patient is a 41-year-old male who is right-hand dominant. He was referred by Dr. Karen Levin, MD, neurology, for evaluation of an injury he sustained to his right medial forearm in June of 2011. He apparently was using a chain saw when he accidentally struck the volar medial aspect of his right forearm in roughly the mid forearm range with a chain saw. He had a large open wound down to muscle. He was seen in the emergency department where the wound is here it at the muscle was sewn together and the skin was closed. He followed up with his primary care provider. He has noted persistent pain which he describes as intermittent and shooting in character radiating from the laceration site. He occasionally has intermittent numbness and tingling in the ring and small finger. He reports grip weakness and no endurance with wrist flexion and gripping. He has not had therapy to date. He did have an EMG/NCS performed by Dr. Levin in August of 2011. Per the patient the study was normal. I do not have that study available at this moment. He currently is not working but is a graphic designer by training. He reports using a computer mouse for 20 minutes causes significant forearm pain.

MEDICATION: Patient has no current medications.

ALLERGIES: nkda

REFERRAL SOURCE: Not Referred By

ILLNESSES: Arthritis

OPERATIONS: Ulnar Nerve Transportation: Active

SOCIAL HISTORY: Alcohol - Denies

Marital Status: Single

Smoking: current every day smoker

FAMILY HISTORY: Diabetes

OCCUPATION: Graphic Designer

ROS:

1. Head and Neck: System reported as normal by patient.
2. Heart: System reported as normal by patient.
3. Lungs: System reported as normal by patient.
4. GI: System reported as normal by patient.
5. GU: System reported as normal by patient.
6. Neuro: As per HPI.
7. Musculoskeletal: As per HPI.
8. Abdomen: System reported as normal by patient.
9. Heme/Lymph: System reported as normal by patient.
10. Other:

PHYSICAL EXAM:

Report Date: June 21, 2012 **Patient:** Dulberg, Paul R **DOS:** 12/02/11**Vitals:**

No data for Vitals.

Appearance:

No distress, good color on room air. Alert and cooperative.

Skin:

Bilateral upper extremities: no open wounds or skin changes.

Neuro:

Bilateral upper extremities: Median, radial and ulnar nerves are motor and sensory intact. Light touch intact all digits, no weakness or wasting.

Vascular:

Bilateral upper extremities: palpable radial pulses and brisk capillary refill.

Focused Exam:

Examination of his right upper extremity reveals his elbow has normal painless range of motion. No focal tenderness to palpation. Collateral ligaments are stable. His forearm compartments are soft. He has a well-healed transverse laceration on the volar medial mid forearm level. There is no erythema, drainage, or fluctuance at the level of the laceration. There is no tenderness to palpation at the laceration site. There is some apparent muscle incongruity. Distally his hand demonstrates no atrophy. He has 5 out of 5 intrinsic strength. 5 out of 5 APB strength. He can make a full fist with full extension of all digits. He does not demonstrate a clawed posture. He has a negative Froment sign. He has a positive Wartenberg sign. Wrist flexion and extension is 5 out of 5 strength. He has a palpable FCU and ECU tendons at the level of the wrist. They have appropriate tension.

IMAGING:

None today.

ASSESSMENT:**DIAGNOSIS:**

906.1-LATE EFFECT OPEN WND EXTREM

PROCEDURES:

99203-NEW Detailed, Low Complexity

PLAN:**Plan:**


I reviewed findings, treatment options, and recommendations with the patient concerning the forearm complaints he has. I would like to see the official report of the EMG/NCS. We will obtain this report. There is no evidence of a complete injury to his ulnar nerve on physical exam. His complaints are likely muscular in origin. He may have some superficial sensory complaints as well. I do not think he needs any surgical intervention at this time. I did recommend and provided him with a prescription for occupational therapy to work on strengthening and conditioning of the forearm muscles. They can also perform some pain control modalities. I would like to see him back in 4-6 weeks' time to see if therapy is of some assistance to him. I will contact him by phone if his EMG is significantly abnormal. Otherwise we will discuss it at the next followup visit. Patient was in agreement with the plan.

Prescription:

No data for Prescription

Work Status:

Not applicable.

_____
Marcus G. Talerico, M.D.

Referred by: Dr. Karen Levin

Primary Care Physician: Dr. Sek

Other: n/a

Fax Created: Dated: 12/5/2011 5:13:04 AM Referred Physician: MC



OAKBROOK TERRACE
1 TransAm Plaza Drive,
Ste. 460
Oakbrook Terrace, IL 60181
P 630.317.7007
F 630.317.7088

LOCKPORT
16610 W. 159th St.
Ste. 103
Lockport, IL 60441
P 708.237.7200
F 708.237.7201

PALOS HEIGHTS
10330 S. Roberts Road
Palos Hills, IL 60465
P 708.237.7200
F 708.237.7201

LIBERTYVILLE
1419 Peterson Road
Libertyville, IL 60048
P 847.247.0547
F 847.247.0540

SCHAUMBURG
1980 East Algonquin Rd.
Ste. 200
Schaumburg, IL 60173
P 847.303.5790
F 847.303.5795

PATIENT: Dulberg, Paul R **AGE:** 41 years old **EXAM DATE:** 01/06/12

HOME: 4648 Aden Court
Mchenry, IL 60051

PID: 1002454

CHIEF COMPLAINT: Right forearm pain.

Nurse's Notes: Patient doesn't feel occupation therapy is helping. He complaints of pain/soreness and loss of strength. MT

Referred by: Not Referred By

HPI: Patient is a 41-year-old male who is right-hand dominant. He was referred by Dr. Karen Levin, MD, neurology, for evaluation of an injury he sustained to his right medial forearm in June of 2011. He apparently was using a chain saw when he accidentally struck the volar medial aspect of his right forearm in roughly the mid forearm range with a chain saw. He had a large open wound down to muscle. He was seen in the emergency department where the wound was debrided and the muscle was sewn together and the skin was closed. He followed up with his primary care provider. He has noted persistent pain which he describes as intermittent and shooting in character radiating from the laceration site. He occasionally has intermittent numbness and tingling in the ring and small finger. He reports grip weakness and no endurance with wrist flexion and gripping. He has not had therapy to date. He did have an EMG/NCS performed by Dr. Levin in August of 2011. Per the patient the study was normal. I saw the patient a proximally one month ago recommended a course of occupational therapy. He has attended one or 2 sessions thus far. I also obtained and the EMG nerve conduction study to review. The patient reports no improvement in symptoms. He thinks that therapy is not helpful. He feels he is getting weaker. He feels burning in the forearm region. He also asked me about disability paperwork.

MEDICAL HISTORY: Arthritis

MEDICATION: naproxen (Dosage: 375 mg Tablet, Delayed Release (E.C.) SIG: Take 1 tablet Oral twice a day Oral Dispense: 90 Refills: 2)

ALLERGIES: nkda

SOCIAL HISTORY Alcohol - Denies

Marital Status: Single

Smoking: current every day smoker

PHYSICAL EXAM:

Appearance: No distress. Alert and cooperative.

Skin: Bilateral upper extremities: no open wounds or skin changes. Well-healed laceration in the mid forearm region right side ulnar aspect. No evidence of infection.

Neuro: Bilateral upper extremities: light touch intact all digits, no weakness or wasting.

Focused Exam: Elbow with full and painless motion in the right side. Forearm compartments are soft there is no obvious deformity. He has preserved wrist flexion and extension strength. He can make a full fist and has full extension of all digits. He has no intrinsic or thenar atrophy. He has 5/5 APB and intrinsic strength. He has a negative Froment sign. He does have a positive Wartenberg sign. FDP to the small finger is 5/5.

IMAGING: None today.


Report Date: June 21, 2012 Patient: Dulberg, Paul R DOS: 01/06/12

DIAGNOSIS: 906.1-LATE EFFECT OPEN WND EXTREM
PROCEDURES: 99213-ESTABLISHED Expanded, Low Complexity

ASSESSMENT & PLAN:

Plan: I reviewed findings, treatment options, and recommendations with the patient concerning the forearm complaints he has. I reviewed the EMG/NCS which is a normal study. There is no evidence of ulnar nerve injury. Given the location of his injury this is the only significant problem I can imagine from this wound. There is no evidence of any nerve or tendon injury. He may have some residual soreness and some superficial sensory abnormalities but this should improve over time. Our recommendation is simply continued therapy. No need for surgical intervention that I can foresee. Unfortunately do not have anything further to offer the patient at this time. I would be happy to see him back in the future on an as needed basis.

Work Status: Not applicable.



Marcus G. Talerico, M.D.

Referred by: Dr. Karen Levin
Other: Hans Mast(Attorney)

Fax Created: Dated 7/9/2012 12:25:12 PM

Fax Created: Dated 7/10/2012 3:13:28 PM